

## PSYCHOSOCIAL IMPACTS OF MAYER–ROKITANSKY–KÜSTER–HAUSER SYNDROME (MÜLLERIAN AGENESIS)

Abdulrahim Gari, M.D.<sup>\*1&2</sup>

<sup>1</sup>Department of Obstetrics and Gynecology, Umm Al-Qura University, Makkah, Saudi Arabia

<sup>2</sup>King Faisal Specialist Hospital and Research Center, Jeddah, Saudi Arabia

### Keywords:

*Müllerian agenesis,  
Mayer–Rokitansky–  
Küster–Hauser  
Syndrome (MRKH),  
Vaginal aplasia, Vaginal  
anomalie.*

### Abstract

**Objectives:** Müllerian agenesis is the congenital absence of the uterus, cervix, and two-thirds of the upper part of the vagina in genetically normal females (46XX). The syndrome has psychological, social, and physical impacts on patients. In this paper, we aimed to explore the social and psychological impacts of Müllerian agenesis before and after reconstructive surgery. An additional aim was to investigate the effect of social media in supporting patients with Müllerian agenesis.

**Methods:** We conducted a survey study of 18 patients aged between 16- to 43-year-old with Müllerian agenesis. A female physician administered a questionnaire via a telephone interview, at least one year after the surgery. Twenty-nine questions that focused on the patients' psychological, social, and sexual status before and after the vaginoplasty and the effect of social media in supporting them and their condition.

**Results:** 8 (44%) patients were diagnosed with Müllerian agenesis in early or mid-adulthood, while 10 (56%) patients knew their diagnosis only after they were married. 12 (66%) patients stated that the surgery had positive effects on their marriage. Satisfaction with sexual performance increased from 58% pre-surgery to 100% post-surgery. 16 (89%) patients reported a positive or somewhat positive impact of a support group (WhatsApp).

**Conclusions:** This paper sheds light on social and psychological aspects of Müllerian agenesis. We emphasize that a multidisciplinary approach is needed to optimize the care and follow-up of patients with this syndrome.

### Introduction

Müllerian agenesis, also known as Mayer–Rokitansky–Küster–Hauser (MRKH) syndrome, is a congenital condition in which a female with a normal genotype (46XX) is born without the upper two-thirds of the vagina and severe hypoplasia or aplasia of the uterus and cervix.<sup>1,2</sup> The syndrome is associated with renal tract anomalies in 15–40% of patients and skeletal system anomalies in 19–20% of cases.<sup>3,4</sup> Females with MRKH syndrome have normal ovaries and secondary sexual characteristics.<sup>2</sup> The incidence of MRKH syndrome is 1 in 5,000 females.<sup>5,6</sup> Some studies have suggested that the syndrome is multifactorial and involves polygenes.<sup>7,8,9</sup> However, until empirical research identifies a chromosomal abnormality in patients with MRKH syndrome, the disease is considered to be *de novo*.<sup>5</sup>

Most patients with MRKH syndrome are diagnosed during the mid-adolescence period.<sup>10</sup> As the syndrome is rare, many individuals encounter difficulties in obtaining a diagnosis and timely psychological support. In addition, as MRKH syndrome results in an inability to have penetrative sexual intercourse and conceive, many patients frequently present with symptoms of depression, inferiority, and low self-esteem, in addition to gender-related concerns. Although many previous studies have described surgical and conservative treatments for MRKH syndrome,<sup>11,12,13</sup> there is little research on psychosocial outcomes and the quality of life in patients with this syndrome.<sup>14</sup> This study aimed to explore psychosocial and sexual outcomes in patients with MRKH syndrome before and after reconstructive surgery. An additional objective was to investigate the effect of social media in supporting patients with MRKH syndrome.

## Methods

This was a survey study of 18 patients aged between 20 - 43 years with MRKH syndrome who were diagnosed in King Faisal Specialist Hospital and Research Center – Jeddah (KFSHRC-J), Saudi Arabia between 2007 and 2015. We constructed a questionnaire based on the Female Sexual Function Index (FSFI),<sup>15</sup> with minor modifications. All the patients underwent vaginoplasty in the same hospital. IRB approval was received from KFSHRC-J in October 11<sup>th</sup>, 2016 with the reference number RC-J/10/38.

Of the 19 patients who underwent surgery (vaginoplasty), one patient refused to participate in the study. The other 18 patients agreed to participate, and verbal consent was obtained from each patient. Karyotyping of each individual was done and the karyotype of all the patients was 46XX.

The questionnaire included 29 questions on demographic data and the patients' psychological, social, and sexual status before and after the vaginoplasty, and the effect of social media in supporting them. It was done after at least one year from the surgery.

## Statistical analysis

As MRKH syndrome is uncommon, the analysis was limited with the small sample size (n=18) to descriptive statistics and compared the proportion before and after the intervention. Continuous data were described using mean, median, and standard deviation. While categorical data were described using proportions. Data were analyzed using STATA 14, College Station, Texas, USA.

## Results

Given the small sample size (n=18), any finding would not be statistically significant. In addition, it cannot be concluded that improvements in sexual desire were related to the patient herself, as many other factors, such as social, mental and marital status determine sexual desire. In terms of sexual desire, 13 (70.6%) of our sample reported a marked improvement in sexual desire, 4 (23.5%) reported a slight improvement and 1 (5.9%) reported no change.

In terms of reaching peak sexual excitement (orgasm), 4 (22%) patients who had responded "never" presurgery responded "always" postsurgery. In addition, 4 (22%) patients stated that they were consistently satisfied/confident with respect to their sexual performance postsurgery as compared to presurgery. 12 (70%) of the 18 patients felt pain presurgery compared to 1 (5.5%) postsurgery, as shown in Figure 1.

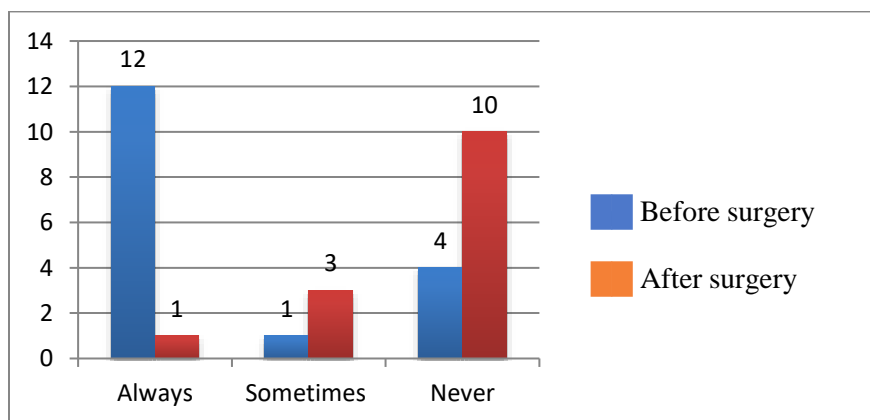
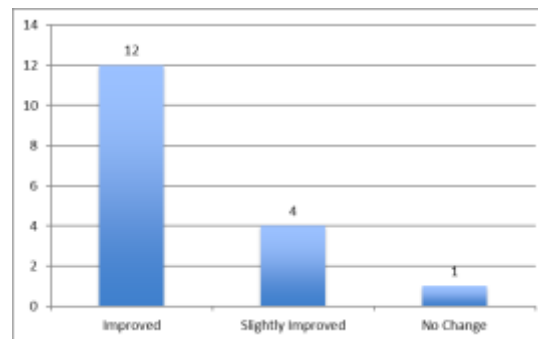


Figure 1. Number of patients who felt pain during sexual intercourse before and after the surgery.

Surprisingly, more than half the patients (10 patients (56%)) were diagnosed only after they were married. 8 (44%) patients were diagnosed with Müllerian agenesis in early or mid-adulthood (17–19 years). Post-diagnosis, the median

time to surgery in all 18 patients was 2 years. In the questionnaire, participants who knew about their diagnosis before marriage were asked whether they had shared this information with their future husbands. Only 8 (44%) of participants responded to this question. Of those who responded, they said that they had told their future husbands about the diagnosis before marriage. According to all 18 participants, there was no family history of MRKH syndrome.



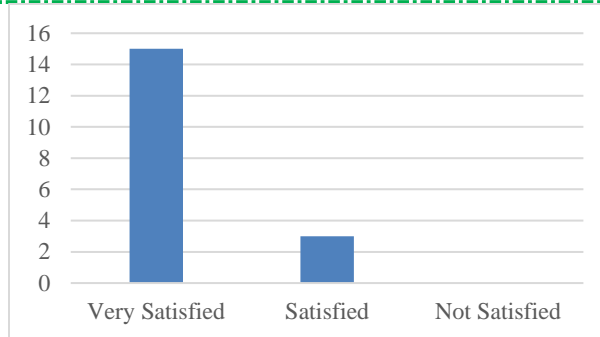
**Figure 2. Number of participants who experienced an improvement in sexual desire after the surgery.**

Of 9 (50%) patients included in the study who were unmarried at the time of the surgery (presurgery), 7 (75%) patients were subsequently married postsurgery.

This was an expected and plausible reason for the change in their social status. When the participants were asked whether the surgery had any effect on their marriage success, 12 (75%) answered “sure,” and 1 (6.3%) answered “somewhat”.

Among the divorced participants (n = 5) who responded to the question about the reasons for getting divorced, 1 (14.3%) patient attributed the divorce to not telling their husband about the diagnosis of MRKH syndrome before marriage, 2 (28.6%) attributed the divorce to experiencing problems with sexual intercourse, and 3 (42.9%) attributed the divorce to the inability to conceive. The divorce rate among the participants might indicate the husbands’ priorities. In the study sample, 12 (80%) of the participants stated that the surgery had a “very” positive impact on their emotional/psychological well-being, whereas 2 (13.3%) stated that it had a “somewhat” positive impact on their emotional/psychological well-being. In response to the question on the impact of MRKH syndrome on their sense of self (feminine self), 12 (66.6%) said it had a major effect, both before and after the surgery, 3 (16.7%) said it had some effect, and 3 (16.7%) said it had no effect.

As expected from previous studies, depression was prevalent in the patients before the vaginoplasty.<sup>16,17</sup> In our sample, 10 (55.5%) patients stated that they felt depressed before the surgery, and only 2 (11%) patients felt depressed after the surgery. In relation to complications postsurgery, 2 (14.3%) stated that they felt pain during intercourse, and 6 (42.8%) reported vaginal dryness during intercourse. In terms of satisfaction with the surgery, 15 (83.3%) of the patients were very satisfied, and 3 (16.7%) were satisfied. None of the patients states not satisfied. Figure 3 provides information on patient satisfaction with the surgery. All 18 patients (100%) stated that they would advise others who have the same syndrome to undergo surgery.



*Figure 3. Patient satisfaction, in general, after the surgery*

In terms of the role of social media, 14 (77.8%) of the patients reported a positive impact of a support group (WhatsApp), and 2 (11%) reported a somewhat positive impact of the support group. Another 1 (5.6%) found that the WhatsApp support group was unhelpful or that it had a negative impact on their emotional well-being. When the patients were asked about uterine transplant surgery, 14 (77.8%) believed it was as important as vaginoplasty, and all the patients considered it complementary to vaginoplasty.

## Discussion

Patients with MRKH syndrome are generally diagnosed in their late adolescent years (17–19 years).<sup>10</sup> However, in our sample, 44% of the patients were diagnosed in early or mid-adulthood. The relatively older age at the time of the diagnosis indicates the barriers that individuals with MRKH syndrome face in accessing medical care and attention in conservative societies like the Kingdom of Saudi Arabia. In the present study it may also be explained by the marriage age (and hence commencement of a sexual relationship) of females in the Kingdom of Saudi Arabia. Nevertheless, in most cases, MRKH syndrome is diagnosed during late adolescence when menstruation fails in individuals with the syndrome.<sup>18</sup> Thus, the reason for the late age at diagnosis in our study remains unclear and cannot be resolved from a survey study. A qualitative study, for example, incorporating a focused (semi-structured) interview or targeted questionnaire is needed to shed light on this issue.

In our study, we found an improvement in sexual desire among the participants after the surgery. Pain during sex decreased markedly post-surgery as compared with that pre-surgery (70% vs. 7%). In addition, pre-surgery, 7 (41%) of the patients stated that they never reached peak sexual excitement (orgasm), whereas only 2 (14%) patients made the same statement post-surgery. Excitement during intercourse increased from 64% pre-surgery to 92% post-surgery. Satisfaction with sexual performance increased from 58% pre-surgery to 100% post-surgery.

The FSFI scores post-surgery pointed to a marked improvement in sexual function. Improved sexual function can be expected to lead to an improved quality of life and psychological and mental well-being.

Our study also focused on social aspects of MRKH syndrome (i.e., the marital status of individuals with the syndrome). Given the rarity of MRKH syndrome, it was difficult to recruit a large sample of patients who had the syndrome, underwent the surgery, and were willing to participate in the study. Of those 8 patients (44%) who responded to the question on sharing their diagnosis with their partners, 5 (62.5%) of them said they had revealed their diagnosis to their future husbands prior to marriage, and 3 (37.5%) said they had not. The low number of respondents to this question is a limitation of the study. In our sample, 5 (27.8%) patients were divorced before the surgery, and another 5 (27.8%) were divorced post-surgery. Of these patients, 7 responded to the question on the reasons underlying the divorce. Among these 7 respondents, 3 (42.9%) patients stated the divorce was due to their inability to conceive, 2 (28.5%) patients said it was due to difficulty engaging in penetrative sexual intercourse, 1 (14.3%) patient said it was

due to not informing their husbands in advance about their diagnosis, and another 1 (14.3%) said it was due to reasons unrelated to their diagnosis.

Both the surgery and support group had very positive effects on the patients' emotional and psychological well-being. As expected from previous studies, depression was prevalent in the patients before the vaginoplasty.<sup>16,17</sup> In our study, feelings of depression improved from 56% pre-surgery to 11% only post-surgery. We also asked the patients about the impact of the surgery on their sense of self (femininity). In our sample, 12 (66.6%) of the patients stated that pre-surgery, the syndrome had a negative impact on their sense of self. Despite reconstruction surgery, gender-related concerns persisted in 12 (66.6%) of the patients after the surgery.

None of the patients in our sample reported a family history of MRKH syndrome. However, it is possible that the participants may have been unwilling to reveal a family history of a such a syndrome in a conservative society. To improve screening of a family history of MRKH syndrome in the future, patients could be asked about a family history of kidney problems, bony problems, or infertility in the family in males, as well as in females. A literature review revealed that males may present with infertility due to the absence of vas deferens or renal abnormalities.<sup>19</sup>

The patients in our sample were enrolled in a social media support group (WhatsApp) immediately upon referral to our hospital. This group was started and monitored by a volunteer female resident (under my supervision) and with the help of an activist (an individual with MRKH syndrome who had similar experience in the past). The use of support groups in the medical setting is not fully developed in Saudi Arabia. Such groups offer a free and easily accessible forum for patients with similar illnesses to support each other.

## Conclusions

In this study, we focused on the emotional and social well-being of patients with MRKH syndrome or Müllerian agenesis. Based on our findings and those in the literature, we conclude that a multidisciplinary approach is required to address the physical, emotional, and social needs of patients with Müllerian agenesis. As shown by this study, psychological support through a social media (WhatsApp) support group was effective for patients with MRKH syndrome. Given the rarity of MRKH syndrome, it is difficult to recruit sufficiently large samples of patients to produce evidence-based research on the syndrome. The establishment of an international excellence center and collaboration between researchers and physicians are suggested to produce more research on different aspects of this uncommon, complex congenital syndrome.

## Acknowledgment

The author thanks Dr. Hanin Alsharif for her support in collection of the data. The author also thanks Dr. Sultan Alwajeeh for his assistance in analyzing the data.

## Declaration of interest

The author reports no conflicts of interest.

## References

1. Bean, E. J.; Mazur, T.; Robinson, A. D. Mayer-Rokitansky-Küster-Hauser Syndrome: Sexuality, Psychological Effects, and Quality of Life. *J. Pediatr. Adolesc. Gynecol.* 2009, 22 (6), 339–346. <https://doi.org/10.1016/j.jpag.2008.11.006>.
2. Morcel, K.; Camborieux, L.; Guerrier, D.; Programme de Recherches sur les Aplasies Müllériennes (PRAM). Mayer-Rokitansky-Küster-Hauser (MRKH) Syndrome. *Orphanet J. Rare Dis.* 2007, 2 (1), 13. <https://doi.org/10.1186/1750-1172-2-13>.
3. Griffin, J. E.; Edwards, C.; Madden, J. D.; Harrod, M. J.; Wilson, J. D. Congenital Absence of the Vagina. *The Mayer-Rokitansky-Küster-Hauser Syndrome.* *Ann. Intern. Med.* 1976, 85 (2), 224–236. <https://doi.org/10.7326/0003-4819-85-2-224>.

4. Guerrier, D.; Mouchel, T.; Pasquier, L.; Pellerin, I. *The Mayer-Rokitansky-Küster-Hauser Syndrome (Congenital Absence of Uterus and Vagina) – Phenotypic Manifestations and Genetic Approaches*. *J. Negat. Results Biomed.* 2006, 5, 1. <https://doi.org/10.1186/1477-5751-5-1>.
5. Edmonds, D. K. *Congenital Malformations of the Genital Tract and Their Management*. *Best Pract. Res. Clin. Obstet. Gynaecol.* 2003, 17 (1), 19–40. <https://doi.org/10.1053/ybeog.2003.0356>.
6. Aittomäki, K.; Eroila, H.; Kajanoja, P. *A Population-Based Study of the Incidence of Müllerian Aplasia in Finland*. *Fertil. Steril.* 2001, 76 (3), 624–625. [https://doi.org/10.1016/s0015-0282\(01\)01963-x](https://doi.org/10.1016/s0015-0282(01)01963-x).
7. Carson, S. A.; Simpson, J. L.; Malinak, L. R.; Elias, S.; Gerbie, A. B.; Buttram, V. C.; Sarto, G. E. *Heritable Aspects of Uterine Anomalies. II. Genetic Analysis of Müllerian Aplasia*. *Fertil. Steril.* 1983, 40 (1), 86–90.
8. Petrozzy, J. C.; Gray, M. R.; Davis, A. J.; Reindollar, R. H. *Congenital Absence of the Uterus and Vagina Is Not Commonly Transmitted as a Dominant Genetic Trait: Outcomes of Surrogate Pregnancies*. *Fertil. Steril.* 1997, 67 (2), 387–389. [https://doi.org/10.1016/S0015-0282\(97\)81927-9](https://doi.org/10.1016/S0015-0282(97)81927-9).
9. Golan, A.; Langer, R.; Bukovsky, I.; Caspi, E. *Congenital Anomalies of the Müllerian System*. *Fertil. Steril.* 1989, 51 (5), 747–755. [https://doi.org/10.1016/s0015-0282\(16\)60660-x](https://doi.org/10.1016/s0015-0282(16)60660-x).
10. Govindarajan, M.; Rajan, R. S.; Kalyanpur, A.; Ravikumar. *Magnetic Resonance Imaging Diagnosis of Mayer-Rokitansky-Kuster-Hauser Syndrome*. *J. Hum. Reprod. Sci.* 2008, 1 (2), 83–85.
11. Davydov, S. N.; Zhvitiashvili, O. D. *Formation of Vagina (Colpopoiesis) from Peritoneum of Douglas Pouch*. *Acta Chir. Plast.* 1974, 16 (1), 35–41.
12. Lilford, R. J.; Johnson, N.; Batchelor, A. *A New Operation for Vaginal Agenesis: Construction of a Neo-Vagina from a Rectus Abdominus Musculo-Cutaneous Flap*. *BJOG Int. J. Obstet. Gynaecol.* 1989, 96 (9), 1089–1094. <https://doi.org/10.1111/j.1471-0528.1989.tb03387.x>.
13. Miller, P. B.; Forstein, D. A. *Creation of a Neovagina by the Vecchiotti Procedure in a Patient with Corrected High Imperforate Anus*. *JSLs* 2009, 13 (2), 221–223.
14. Heller-Boersma, J. G.; Schmidt, U. H.; Edmonds, D. K. *Psychological Distress in Women with Uterovaginal Agenesis (Mayer-Rokitansky-Kuster-Hauser Syndrome, MRKH)*. *Psychosomatics* 2009, 50 (3), 277–281. <https://doi.org/10.1176/appi.psy.50.3.277>.
15. Rosen, R.; Brown, C.; Heiman, J.; Leiblum, S.; Meston, C.; Shabsigh, R.; Ferguson, D.; D'Agostino, R. *The Female Sexual Function Index (FSFI): A Multidimensional Self-Report Instrument for the Assessment of Female Sexual Function*. *J. Sex Marital Ther.* 2000, 26 (2), 191–208. <https://doi.org/10.1080/009262300278597>.
16. Chen, N.; Song, S.; Duan, Y.; Kang, J.; Deng, S.; Pan, H.; Zhu, L. *Study on Depressive Symptoms in Patients with Mayer-Rokitansky-Küster-Hauser Syndrome: An Analysis of 141 Cases*. *Orphanet J. Rare Dis.* 2020, 15 (1), 121. <https://doi.org/10.1186/s13023-020-01405-9>.
17. Laggari, V.; Diareme, S.; Christogiorgos, S.; Deligeoroglou, E.; Christopoulos, P.; Tsiantis, J.; Creatsas, G. *Anxiety and Depression in Adolescents with Polycystic Ovary Syndrome and Mayer-Rokitansky-Küster-Hauser Syndrome*. *J. Psychosom. Obstet. Gynaecol.* 2009, 30 (2), 83–88. <https://doi.org/10.1080/01674820802546204>.
18. *Mayer-Rokitansky-Küster-Hauser (MRKH) Syndrome - Symptoms and Causes* <https://www.pennmedicine.org/for-patients-and-visitors/patient-information/conditions-treated-a-to-z/mayer-rokitansky-kuster-hauser-mrkh-syndrome> (accessed Jan 24, 2021).
19. Hamada, A. J.; Esteves, S. C.; Agarwal, A. *A Comprehensive Review of Genetics and Genetic Testing in Azoospermia*. *Clinics* 2013, 68 (Suppl 1), 39–60. [https://doi.org/10.6061/clinics/2013\(Sup01\)06](https://doi.org/10.6061/clinics/2013(Sup01)06).